

# Human embryonic stem cell-derived retinal pigment epithelium in patients with age-related macular degeneration and Stargardt's macular dystrophy: follow-up of two open-label phase 1/2 studies



Steven D Schwartz, Carl D Regillo, Byron L Lam, Dean Elliott, Philip J Rosenfeld, Ninel Z Gregori, Jean-Pierre Hubschman, Janet L Davis, Gad Heilwell, Marc Spirn, Joseph Maguire, Roger Gay, Jane Bateman, Rosaleen M Ostrick, Debra Morris, Matthew Vincent, Eddy Anglade, Lucian V Del Priore, Robert Lanza

## Summary

**Background** Since they were first derived more than three decades ago, embryonic stem cells have been proposed as a source of replacement cells in regenerative medicine, but their plasticity and unlimited capacity for self-renewal raises concerns about their safety, including tumour formation ability, potential immune rejection, and the risk of differentiating into unwanted cell types. We report the medium-term to long-term safety of cells derived from human embryonic stem cells (hESC) transplanted into patients.

**Methods** In the USA, two prospective phase 1/2 studies were done to assess the primary endpoints safety and tolerability of subretinal transplantation of hESC-derived retinal pigment epithelium in nine patients with Stargardt's macular dystrophy (age >18 years) and nine with atrophic age-related macular degeneration (age >55 years). Three dose cohorts (50 000, 100 000, and 150 000 cells) were treated for each eye disorder. Transplanted patients were followed up for a median of 22 months by use of serial systemic, ophthalmic, and imaging examinations. The studies are registered with ClinicalTrials.gov, numbers NCT01345006 (Stargardt's macular dystrophy) and NCT01344993 (age-related macular degeneration).

**Findings** There was no evidence of adverse proliferation, rejection, or serious ocular or systemic safety issues related to the transplanted tissue. Adverse events were associated with vitreoretinal surgery and immunosuppression. 13 (72%) of 18 patients had patches of increasing subretinal pigmentation consistent with transplanted retinal pigment epithelium. Best-corrected visual acuity, monitored as part of the safety protocol, improved in ten eyes, improved or remained the same in seven eyes, and decreased by more than ten letters in one eye, whereas the untreated fellow eyes did not show similar improvements in visual acuity. Vision-related quality-of-life measures increased for general and peripheral vision, and near and distance activities, improving by 16–25 points 3–12 months after transplantation in patients with atrophic age-related macular degeneration and 8–20 points in patients with Stargardt's macular dystrophy.

**Interpretation** The results of this study provide the first evidence of the medium-term to long-term safety, graft survival, and possible biological activity of pluripotent stem cell progeny in individuals with any disease. Our results suggest that hESC-derived cells could provide a potentially safe new source of cells for the treatment of various unmet medical disorders requiring tissue repair or replacement.

**Funding** Advanced Cell Technology.

## Introduction

Since 1981, when pluripotential cell cultures were first derived by Evans and Kauffman,<sup>1</sup> embryonic stem cells (ESC) have been regarded as a potential source of therapeutic cells for a wide range of diseases caused by tissue loss or dysfunction.<sup>2</sup> Despite the great therapeutic potential, their plasticity and unlimited capacity for self-renewal raise concerns about serious safety issues, including the ability to form teratomas and other tumours, potential immune reactions, and the risk of differentiating into unwanted cell types. Although ESC have been extensively studied in vitro and in animals for more than three decades, there have

been no reports of the assessment of their long-term safety and potential effectiveness in treating human disease.

The use of ESC has been proposed for the treatment of a wide range of disorders, including myocardial regeneration after myocardial infarction, islet cell replacement in patients with diabetes, and neural cell replacement in ischaemic stroke, Parkinson's disease, and Alzheimer's disease.<sup>2</sup> However, because of its immunoprivileged nature (ability to tolerate foreign antigens or non-histocompatible cells without eliciting an immune response), diseases affecting the eye are attractive first-in-human applications for this technology.

Published Online  
October 15, 2014  
[http://dx.doi.org/10.1016/S0140-6736\(14\)61376-3](http://dx.doi.org/10.1016/S0140-6736(14)61376-3)  
See Online/Comment/  
[http://dx.doi.org/10.1016/S0140-6736\(14\)61820-1](http://dx.doi.org/10.1016/S0140-6736(14)61820-1)

Jules Stein Eye Institute Retina Division, and David Geffen School of Medicine, University of California, Los Angeles, CA, USA (Prof S D Schwartz MD, J-P Hubschman MD, G Heilwell MD, R M Ostrick MPH); Wills Eye Hospital and Thomas Jefferson University, Philadelphia, PA, USA (Prof C D Regillo MD, M Spirn MD, J Maguire MD); Bascom Palmer Eye Institute, University of Miami, Miami, FL, USA (Prof B L Lam MD, N Z Gregori MD, Prof P J Rosenfeld MD, Prof J L Davis MD); Massachusetts Eye and Ear Infirmary and Harvard Medical School, Boston, MA, USA (D Elliott MD); Advanced Cell Technology, Marlborough, MA, USA (R Gay PhD, J Bateman RN, D Morris MPH, M Vincent PhD, E Anglade MD, Prof R Lanza MD); and Storm Eye Institute, Medical University of South Carolina, Charleston, SC, USA (Prof L V Del Priore MD)

Correspondence to:  
Prof Robert Lanza, Advanced Cell Technology, Marlborough, MA 01752, USA  
[rlanza@advancedcell.com](mailto:rlanza@advancedcell.com)  
or

Prof Steven D Schwartz, Retina Division, Jules Stein Eye Institute, Los Angeles, CA 90095, USA  
[schwartz@jsei.ucla.edu](mailto:schwartz@jsei.ucla.edu)

See Online for appendix

The subretinal space is protected by the blood-ocular barrier, and is characterised by antigen-specific inhibition of both the cellular and humoral immune responses.<sup>3</sup> For locally delivered, intraocular treatments, low doses are needed compared with systemic therapies, and meaningful extraocular biodistribution is rare.

Degeneration of the retinal pigment epithelium leads to photoreceptor loss in several sight-threatening diseases, rendering it an attractive regenerative target. In atrophic age-related macular degeneration, genetic and environmental factors predispose patients to immune mediated and oxidative stresses that ultimately compromise the retinal pigment epithelium. In Stargardt's macular dystrophy, degeneration of the retinal pigment epithelium is typically induced by genetically altered photoreceptor outer segments. Respectively, these macular degenerations are two of the leading causes of adult and juvenile blindness in developed countries. The non-exudative (dry) form of age-related macular degeneration accounts for 80–90% of all cases and is currently untreatable. Similarly, there are no known treatments to prevent or reverse the loss of vision in patients with Stargardt's macular dystrophy.

There is evidence that subretinal transplantation of hESC-derived retinal pigment epithelium can rescue photoreceptors and prevent visual loss in preclinical models of macular degeneration.<sup>4,5</sup> The retinal pigment epithelium maintains the health of photoreceptors by recycling photopigments, metabolising and storing vitamin A, phagocytosing shed photoreceptor segments, and other functions.<sup>6,7</sup> In preclinical models, transplantation of hESC-retinal pigment epithelium resulted in extensive photoreceptor rescue and improvement in visual function.<sup>4</sup> The results of these and other studies<sup>8</sup> suggest that hESC could be a potentially safe source of retinal pigment epithelium for treatment of retinal degenerative diseases. Although transplantation of primary retinal pigment epithelium cells has been attempted in people, the results have been mixed for both graft survival and visual improvement.<sup>9–16</sup> There are important advantages to using cells derived from pluripotent stem cell sources, including the ability to have a virtually unlimited supply of cells and to control their differentiation to ensure optimum safety and potency before transplantation. We report the medium-term and long-term results of two prospective clinical trials done in the USA to investigate the safety and tolerability of hESC-derived retinal pigment epithelium in patients with atrophic age-related macular degeneration or Stargardt's macular dystrophy.

## Methods

### Patients and procedures

For two phase 1/2 studies in the USA, 18 patients (nine with atrophic age-related macular degeneration and nine with Stargardt's macular dystrophy) were selected from four centres in accordance with the inclusion and

exclusion criteria, including end-stage disease, genotyping, central visual loss, and absence of other significant ophthalmic pathology (appendix). The protocols were approved by the institutional review boards and ethics committees of the respective sites. Written informed consent was obtained from all the patients.

The hESC and hESC-derived retinal pigment epithelium cells were generated as previously described.<sup>17</sup> Briefly, vials of hESC-MA09 were thawed, expanded, and differentiated into pigmented retinal pigment epithelium patches in accordance with the current good manufacturing practices. The hESC-retinal pigment epithelium cells were assessed for safety and characterised for retinal-pigment-epithelium-specific attributes at various times (appendix).

Vials of cryopreserved hESC-retinal pigment epithelium cells were thawed, formulated, Gram stained, and delivered to the operating room.<sup>17</sup> Pars plana vitrectomy, including the surgical induction of posterior vitreous separation from the optic nerve anteriorly to the posterior border of the vitreous base, was done in the eye with the worse vision. 150 µL of retinal pigment epithelium was injected through a MedOne PolyTip Cannula 23/38 or 25/38 (MedOne Surgical, Sarasota, FL, USA), delivering the targeted dose of viable retinal pigment epithelium cells into the subretinal space in sites with a preselected transition zone (the area between atrophic photoreceptor, retinal pigment epithelium, and choriocapillaris and fairly healthy post-equatorial retina) as the centre as assessed with autofluorescence and optical coherence tomography imaging. Transplantation sites were chosen carefully on the basis of the presence of native, albeit compromised, retinal pigment epithelium and similarly compromised overlying photoreceptors to optimise the chances of transplant integration and potential for photoreceptor cell rescue.

Three dose cohorts were treated for each disorder: cohort 1, 50 000 cells (three patients with Stargardt's macular dystrophy and three with age-related macular degeneration); cohort 2, 100 000 cells (three patients with Stargardt's macular dystrophy and three with age-related macular degeneration); and cohort 3, 150 000 cells (three patients with Stargardt's macular dystrophy and three with age-related macular degeneration). The oral systemic immunosuppression regimen included tacrolimus and mycophenolate mofetil 1 week before the surgical procedure and continued for 12 weeks (appendix).

### Outcomes

The primary endpoints were the safety and tolerability of hESC-derived retinal pigment epithelium in patients with atrophic age-related macular degeneration or Stargardt's macular dystrophy. The secondary endpoints were the efficacy of hESC-derived retinal pigment epithelium: transplanted patients were followed up with serial ophthalmic examinations—best-corrected visual acuity, visual field testing, slit-lamp biomicroscopy, ophthalmoscopy, optical coherence tomography,

fluorescein angiography, autofluorescence imaging, fundus photography, and electroretinography. Systemic monitoring was physical examinations, vital signs, electrocardiograms, cancer screening, and haematological and serological testing as part of study-specific procedures for both studies.

### Statistical analysis

The sample size in these studies was not based on statistical power calculations. The size of the patient population in the studies was not sufficient to permit a conclusive statistical analysis. Summary data for each dose group and for the two study populations were used for the assessment of adverse events, quality of life, and visual acuity information.

The studies are registered with ClinicalTrials.gov, numbers NCT01345006 (Stargardt's macular dystrophy) and NCT01344993 (age-related macular degeneration).

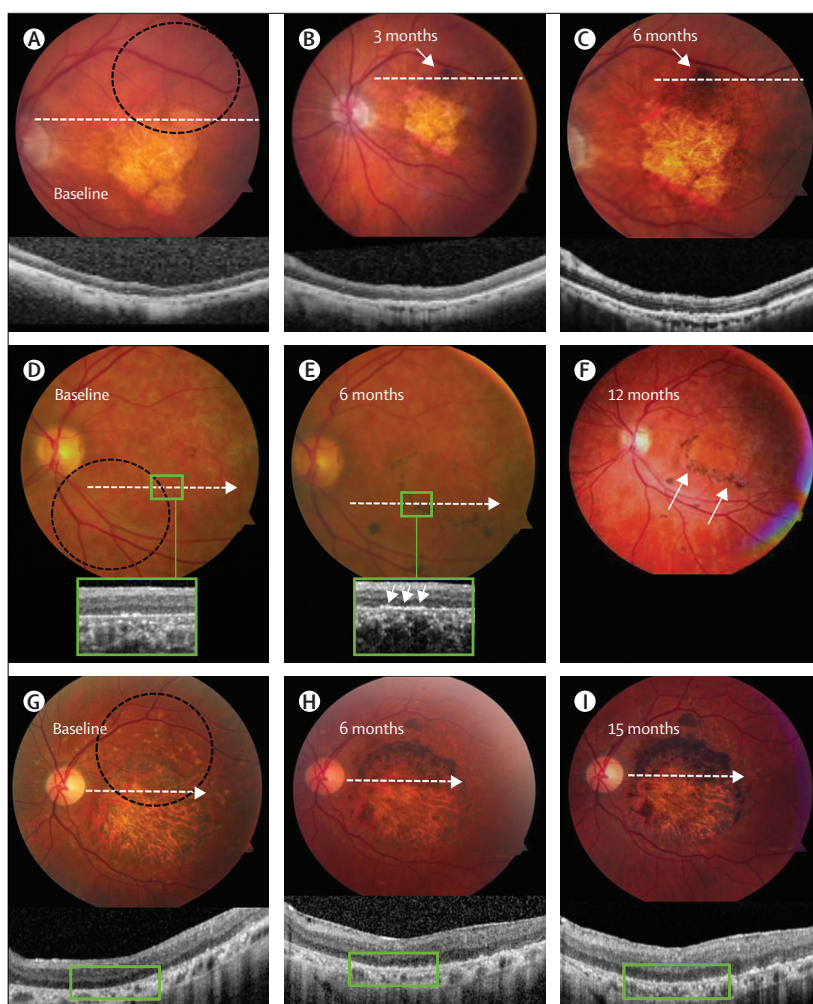
### Role of the funding source

The funder of the study participated in the study design, data gathering, analysis, and interpretation, and writing of the report. The corresponding authors had full access to all the data in the study and had final responsibility for the decision to submit for publication.

### Results

In two phase 1/2 studies, nine patients (five female, eight white and one black) were enrolled from July 12, 2011, to Jan 22, 2014, in the Stargardt's macular dystrophy trial and nine patients (six female, all white) were enrolled from July 12, 2011, to Oct 15, 2013, in the age-related macular degeneration trial. The median age was 77 years (range 70–88) in the patients with age-related macular degeneration and 50 years (20–71) in those with Stargardt's macular dystrophy. Transplanted patients were followed up for a median of 22 months (four patients for <12 months; 12 patients for 12–36 months, and two patients for >36 months).

After surgery, 13 (72%) of 18 patients had an increase in subretinal pigmentation, consistent with transplanted retinal pigment epithelium (figure 1). For both age-related macular degeneration and Stargardt's macular dystrophy, pigmented tissue was present typically at the border of the atrophic lesion and increased in density and size with time after surgery (figure 1). Optical coherence tomography imaging of these transplanted areas showed findings consistent with a layer of cells lining aspects of Bruch's membrane (figure 1, insets for D and E). Preretinal, pigmented cell growth was seen in three eyes (one patient with Stargardt's macular dystrophy and two patients with age-related macular degeneration) near the injection site that did not seem to contract (figure 2B, D, E, F, and H). Typically this growth was seen as a small patch of epiretinal pigmented tissue with biomicroscopy and optical coherence tomography. No adverse effects were caused by these small epiretinal pigmented cell

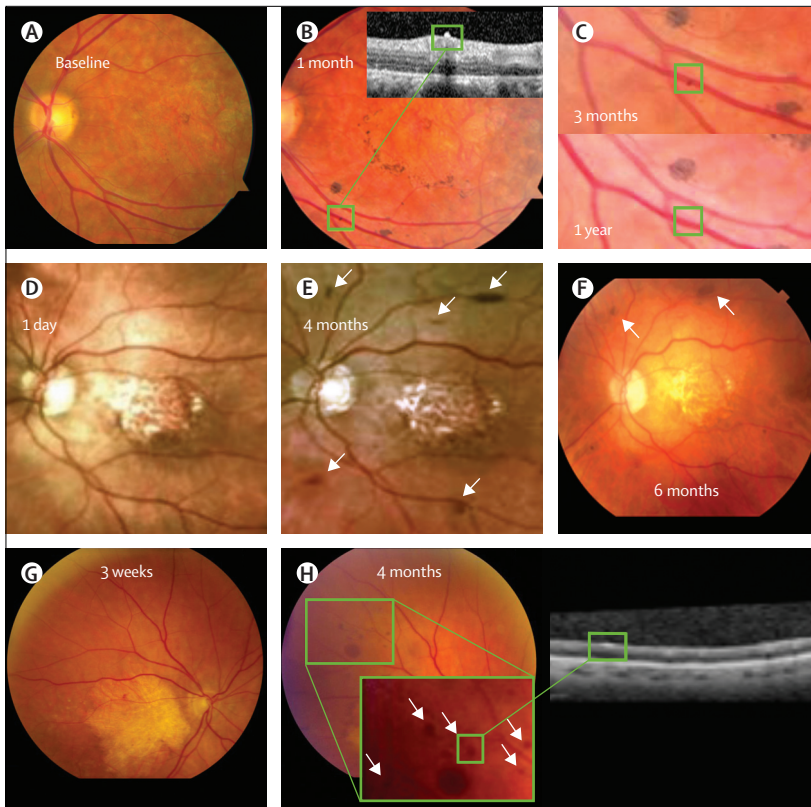


**Figure 1:** Fundus images of eyes with pigmentation after transplantation with hESC-retinal pigment epithelium (A–C) Colour fundus photographs and SD-OCT images at baseline of an eye from a patient with age-related macular degeneration (dotted circle shows an outline of the transplanted area), 3 months, and 6 months. Note the presence of a pigmented patch of transplanted cells (B and C, arrows) that becomes larger and more pigmented by 6 months. OCTs (inset) show the presence of cells on the inner aspects of Bruch's membrane at 6 months compared with baseline. (D–F) Colour fundus photographs and SD-OCT images at baseline of an eye from a patient with Stargardt's macular dystrophy (dotted circle shows an outline of the transplanted area), 6 months, and 1 year. Note the absence of pigment in the preoperative photograph (D). Patches of pigmented cells are evident around the border of baseline atrophy in retinal pigment epithelium (E) that become more prominent at 1 year (F, arrows). SD-OCT images at baseline (D) and 6 months (E) show increasing pigmentation is at the level of the retinal pigment epithelium, normal monolayer retinal pigment epithelium engraftment, and survival at 6 months (E, arrows) adjacent to a region of bare Bruch's membrane devoid of native retinal pigment epithelium. (G–I) Colour fundus photographs of a patient with Stargardt's macular dystrophy (dotted circle shows an outline of the transplanted area). A large central area of atrophy is visible on the preoperative photograph (G). An area of transplanted retinal pigment epithelium cells is visible at the superior half of the atrophic lesion at 6 months (H) that becomes larger and more pigmented at 15 months (I). hESC=human embryonic stem cells. SD-OCT=spectral domain optical coherence tomography. OCT=optical coherence tomography.

patches; specifically, there was no post-surgical macular pucker, defined as an undulation of the inner limiting membrane and inner retinal lamellae, in any eyes.

Interpretation of autofluorescence imaging is complex in both the disorders studied. Postoperatively there was variation in the autofluorescence signature arising from the pigmented cells that was seen after transplantation. In some eyes, there was no change in the autofluorescence





**Figure 2: Preretinal cell growth**

Pigmented preretinal growths were seen in the eyes of three patients. The fundus photograph and OCT show a small pigmented clump, perhaps a single cell, in a patient with Stargardt's macular dystrophy 1 month after transplantation (B) compared with baseline (A). The clump resolved and is no longer visible at 12 months (C). Fundus images before the development of the preretinal growths (D and G). Two patients with age-related macular degeneration also developed preretinal growths several months after transplantation that were visible on postoperative photographs and OCT (E and H). Growth and advancement of the cells subsided by 6–9 months in both patients (F, and data not shown). No adverse clinical effects were noted from these small epiretinal pigmented patches. OCT=optical coherence tomography.

after surgery. In other cases, areas of fairly normal intensity autofluorescence corresponding to transplanted retinal pigment epithelium seemed to appear after surgery. In one eye, pigmented cells transplanted into the atrophic central macula showed a clear, bright autofluorescent signal over the first few follow-up assessments that faded over time (appendix). Although visual field, static perimetry, electroretinography, and reading speed were tested in these patients, no clear differences were seen between pretransplantation and post-transplantation.

Four treated eyes developed visually significant progression of cataract—two patients (one with age-related macular degeneration and one with Stargardt's macular dystrophy) requiring cataract surgery 6–12 months after surgery, and two patients with Stargardt's macular dystrophy undergoing elective surgery after the first year). One eye in a patient with Stargardt's macular dystrophy developed severe vitreous cavity inflammation consistent with acute postoperative endophthalmitis 4 days after the surgery (appendix). Vitreous cultures grew *Staphylococcus*

*epidermidis*, and the inflammation resolved over 2 months after intravitreal antibiotic injection, antibiotic eye drops, and discontinuation of immunosuppression. Importantly, cultures and Gram stains of the hESC-retinal pigment epithelium preparations were negative. Vision returned to baseline by month 3 and there was no evidence of subretinal infection.

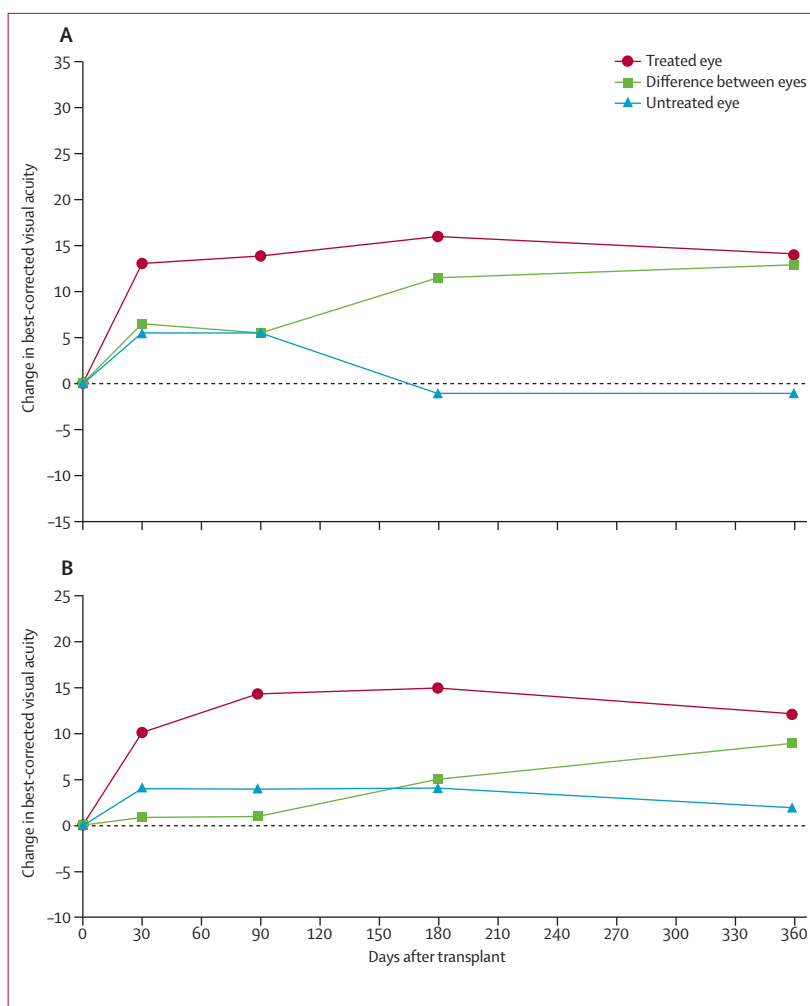
Additionally, one eye developed vitreous inflammation characterised by an inferior transvitreal band at post-transplant week 3 that did not lead to macular pucker or a traction retinal detachment; this band resolved spontaneously by month 6 (appendix). Prominent lymphocyte infiltration, acute or chronic moderate grade non-infectious uveitis, hyperacute rejection, cystoid macular oedema, or other signs of acute transplant rejection were not noted in any of the operated eyes. Specifically, there was no encapsulation of the transplanted cells and there was no retinal or subretinal whitening in the transplanted area. Additionally, there were no occurrences of adverse proliferation, growth of transplanted tissue at the injection site that was suggestive of a teratoma, ectopic tissue (non-retinal pigment epithelium), or other significant ocular adverse safety issues related to the hESC-retinal pigment epithelium cells in any patient during the observation period. No eyes developed retinal detachment, proliferative vitreoretinopathy, or microvascular occlusions. One eye showed a persistent subretinal bleb at the injection site that spontaneously resolved in 2 days, and one eye developed a mild epiretinal membrane (appendix). Importantly, no discernible angiographic changes were noted in the pattern of vascular filling of the retinal vascular or choroidal vascular circulations up to 1 year after surgery. One eye developed what seemed to be focal defects in the native retinal pigment epithelium at the time of surgery, suggesting subretinal pigment epithelium injection (appendix). However, there was no adverse clinical effect and the patient's visual acuity improved by 16 letters relative to baseline 1 year after transplantation. One eye showed some mild, late fluorescein angiographic leakage at 1 month in an area that had not been imaged preoperatively (appendix). The immunosuppressive regimen was not modified and the finding resolved by month 3. Several systemic adverse events (appendix) classified as being related to treatment were likely related to the immune suppression, which is known to cause systemic issues in transplant recipients.

Preoperatively, the best-corrected Early Treatment of Diabetic Retinopathy Study visual acuity (best-corrected visual acuity) in the study eyes ranged from 20/200 (severe vision loss) to hand motion (near blindness; appendix). At 6 months after transplant, visual acuity for the nine patients with age-related macular degeneration improved from baseline by at least 15 letters in four eyes, improved by 11–14 letters in two eyes, and remained stable (change of less than or equal to ten letters) in three eyes; and for the seven patients with follow-up at

12 months after transplant, three eyes had an increase of at least 15 letters, one eye had an improvement of 13 letters, and three were stable (change of less than or equal to ten letters). Visual acuity in the eight patients (one patient did not have a 6-month assessment) with Stargardt's macular dystrophy at the 6-month assessment was improved by at least 15 letters in three eyes, remained stable (change of less than or equal to ten letters) in four eyes, and decreased by 11 letters in one eye. Seven patients with Stargardt's macular dystrophy had visual acuity assessments at 12 months—three had an increase of at least 15 letters, three were stable (change of less than or equal to ten letters), and one had a decrease of more than ten letters.

For age-related macular degeneration, treated eyes that did not develop cataracts during at least 6 months of follow-up ( $n=8$ ) improved by a median of 13 letters (IQR 3·8 to 31·8) at 1 month, 14 letters (5·5 to 23·8) at 3 months, 16 letters (4·3 to 18·8) at 6 months, and 14 letters (3·0 to 19·0) at 12 months (figure 3A), whereas the fellow eyes improved by a median of six letters (−3·5 to 10·9) at 1 month and six letters (−1·5 to 8·7) at 3 months, and did not improve at 6 months (reduction of one letter [−1·0 to −6·0]) and 12 months (reduction of one letter [−5·0 to 6·1]; figure 3A). The median difference in change from baseline in visual acuity at 12 months between the treated eyes and the untreated eyes that did not develop cataracts or have ocular surgery during the follow-up was eight letters (range 4–23) for dose group 1 (50 000 cells;  $n=3$ ), eight letters (range 2–14) for dose group 2 (100 000 cells;  $n=2$ ), and 15 letters (range 13–44) for dose group 3 (150 000 cells;  $n=3$ ). The difference in the change from baseline in visual acuity at 12 months between treated and untreated eyes that did not develop cataract ( $n=8$ ; one individual was excluded who had laser surgery for posterior capsular opacity in the untreated eye before the 12-month assessment) was significant ( $p=0\cdot0117$ , Wilcoxon signed-rank, two-tailed test).

For Stargardt's macular dystrophy, treated eyes that did not develop cataracts during at least 6 months of follow-up ( $n=5$ ) improved by a median of ten letters (IQR −4·5 to 14·0) at 1 month, 14 letters (−3·5 to 16·0) at 3 months, 15 letters (−2·0 to 17·0) at 6 months, and 12 letters (−2·5 to 21·0) at 12 months (figure 3B), whereas the fellow eyes improved by a median of four letters (IQR −0·5 to 12·0) at 1 month, four letters (−0·5 to 11·5) at 3 months, four letters (−1·0 to 9·5) at 6 months, and two letters (−1·5 to 12·0) at 12 months (figure 3B). The median difference in change from baseline in visual acuity at 12 months between the treated and untreated eyes that did not develop cataracts was nine letters (range 9–9) for dose group 1 (50 000 cells;  $n=3$ ), two letters for dose group 2 (100 000 cells;  $n=1$ ), and five letters (range 0–10) for dose group 3 (150 000 cells;  $n=2$ ). The median difference in change from baseline in visual acuity at 12 months between the treated and untreated eyes that



**Figure 3:** Change from baseline in best-corrected visual acuity in patients with age-related macular degeneration (A) and Stargardt's macular dystrophy (B)

Median change in best-corrected visual acuity was expressed as number of letters read on the Early Treatment of Diabetic Retinopathy Study visual acuity chart in patients with age-related macular degeneration (A) and Stargardt's macular dystrophy (B). Red lines show treated eyes and blue lines show untreated eyes of patients during the first year after transplantation of the cells derived from human embryonic stem cells. Green lines show the difference between treated and untreated eyes. Patients who underwent cataract surgery after transplantation are not included in the graph. There was a significant difference in the letters read in transplanted eyes of patients with age-related macular degeneration versus non-transplanted controls at 12 months (median 14 letters vs −1 letter;  $p=0\cdot0117$ ). There was an increase in letters read in transplanted eyes of patients with Stargardt's macular dystrophy versus non-transplanted controls at 12 months (median 12 letters vs two letters, although the sample size was too small to allow reliable calculation of the Wilcoxon signed-rank test).

did not develop cataracts ( $n=5$ ) was not significant (the sample size was too small to reliably calculate the Wilcoxon signed-rank test).

Two of the four patients who developed cataracts (one with age-related macular degeneration and one with Stargardt's macular dystrophy) had a decrease in visual acuity (three to 12 letters) during cataract progression, but visual acuity returned to baseline after cataract surgery, whereas the other two patients (both with Stargardt's macular dystrophy) had increases in visual acuity (six to seven letters) during cataract progression, which increased further after cataract surgery (nine to 15 letters).

The National Eye Institute Visual Function Questionnaire 25, regarded as a sensitive and reliable instrument for the measurement of vision-targeted quality of life, was administered by trained examiners at pretreatment and at various timepoints after transplantation.<sup>18,19</sup> For the patients with age-related macular degeneration, the mental health and vision subscales for general vision, peripheral vision, near activities, and distance activities improved from baseline by a median of 16–25 points 3–12 months after transplantation (appendix). For patients with Stargardt's macular dystrophy, the mental health and vision subscales for general vision, peripheral vision, near activities, and distance activities improved by a median of 8–20 points 3–12 months after transplantation (appendix).

### Discussion

Our results show that hESC-derived cells were well tolerated for up to 37 months after transplantation in individuals with atrophic age-related macular degeneration and Stargardt's macular dystrophy. So far, in the two clinical trials, there were no serious adverse safety signals attributed to the transplanted cells. Potential safety concerns about the use of hESC in people, including the possibility of teratoma formation, immune reactions, and the risk of cells differentiating into unwanted ectopic cell types were not noted. According to literature reports,<sup>20–22</sup> teratoma formation was expected to arise within the first few months after transplantation, but this was not the case in our patients who have been followed up for a median of 22 months. To the best of our knowledge, this is the first report of the results of medium-term to long-term safety and tolerability after transplantation of cells derived from pluripotent stem cells in individuals with any disease (panel).

Surgical complications of vitreoretinal surgery are well characterised. The complications reported here are consistent with the risks that are associated with pars

plana vitrectomy surgery for macular disorders,<sup>25</sup> and thus in the patient groups we studied there seem to be no complications associated specifically with hESC-derived retinal pigment epithelium. Three eyes developed visually insignificant, preretinal patches of non-contractile, transplanted retinal pigment epithelium presumably refluxed from the subretinal space or injected into the preretinal space.

One patient developed endophthalmitis, which is known to occur after vitrectomy.<sup>26</sup> *Staphylococcus epidermidis* was detected in the vitreous cultures from this patient but not in Gram-stained or cultured donor cells. Infection was not detected in the subretinal space. Recovery to baseline visual acuity occurred by 3 months after surgery and there were no apparent long-term sequelae of the infection. Complications were associated with systemic immunosuppression in some of the older patients with age-related macular degeneration (appendix), suggesting that future trials might include a modified immunosuppression regimen for older patients.

We noted an increase in subretinal pigmentation in 13 of 18 patients consistent with successfully transplanted hESC-retinal pigment epithelium. However, there was no correlation between the presence of postoperative pigmentation and postoperative visual improvement, and the absence of hyperpigmentation did not preclude the possibility of visual improvement. These findings are consistent with those from preclinical studies in which survival and integration of the transplanted hESC-retinal pigment epithelium cells into the host monolayer could only be detected with immunohistochemistry rather than by an increase in pigment.<sup>4,5</sup> We did not detect prominent lymphocyte infiltration, hyperacute rejection, uveitis, or other signs of acute graft rejection in the operative eyes. However, this does not exclude graft rejection in these patients. Since there is immune privilege in the subretinal space,<sup>3</sup> rejection can be manifested by cell loss alone after transplantation,<sup>27</sup> or by progressive loss of function in the absence of inflammation.<sup>28</sup> It is not certain that immune privilege occurs in people with macular disease, but our results suggest that safety parameters such as visual acuity were stable or improved during the follow-up.

Thus, the subretinal space might be an ideal target for complex biological treatments, as shown by data from a gene therapy trial.<sup>29</sup> In our study, the subretinal patches of pigmented cells continued to increase in size or remained stable over time, but we recognise that pigment is not an absolute marker for transplanted cells. Results with animal models have shown that cell survival and engraftment might be present without clinically visible pigmentation.<sup>4,5</sup> Comparison of the eyes with and without visible subretinal pigmented tissue did not show any correlation between the development of pigment and improvement in visual acuity (data not shown). Explanations for the lack of correlation might be that the

#### Panel: Research in context

##### Systematic review

We searched PubMed for all publications, including clinical trials, meta-analyses, and reviews, for all years available, and without any language restrictions, with the terms "age-related macular degeneration", "dry-AMD", "Stargardt's macular dystrophy", "Stargardt's disease", "embryonic stem cells", and "stem cells" and found no similar studies. Although several new drugs are available for the treatment of the exudative (wet) type of age-related macular degeneration, no proven treatments exist for patients with geographic atrophy (dry age-related macular degeneration).<sup>23</sup> Evidence from preclinical animal models suggests that stem cells could be useful as part of new treatment strategies for currently incurable degenerative retinal diseases.<sup>24</sup>

##### Interpretation

Our study provides the first evidence of the medium-term to long-term safety, survival, and possible biological activity of pluripotent stem cell progeny after transplantation in people with any disease. The results suggest that human-embryonic-stem-cell-derived cells could provide a potentially safe new source of cells for the treatment of various medical disorders that require tissue repair or replacement.

subretinal pigmentation represented only a fraction of the transplanted retinal pigment epithelium, with the rest of the transplanted retinal pigment epithelium integrated into the compromised native retinal pigment epithelium layer without a hyperpigmentation signal; subretinal pigmentation represented all of the transplanted retinal pigment epithelium, but not adjacent to viable photoreceptors and thus did not affect the visual function; and subretinal pigmentation did not represent the transplanted retinal pigment epithelium, but represented macrophages or native cells ingesting pigment. However, as noted above, one eye developed a very clear hyperautofluorescent signal emanating from transplanted hyperpigmented tissue within the bed of completely atrophic central macula (appendix). This autofluorescent signal is consistent with these cells being transplanted retinal pigment epithelium, but is not proof because there are other possible explanations.

Although the testing of best-corrected visual acuity was done as a safety parameter to monitor for loss of vision, improvement in visual acuity occurred in more than half of the eyes treated. Eight of 18 patients had an improvement in visual acuity of at least 15 letters during the first year after surgery, which corresponds to doubling of the visual angle, and is generally accepted as a clinically significant measure of improvement in clinical trials.<sup>30,31</sup> Participants in this study also reported a notable improvement in their general vision, near and distance activities, and peripheral vision as measured with the National Eye Institute Visual Function Questionnaire 25 subscales.

Untreated eyes did not show similar improvements in visual acuity, which suggests biological activity of the transplanted cells, but other explanations might be the well known rescue effect of sham surgery on some retinal degenerations.<sup>32,33</sup> Additionally, the possibility of a placebo effect and examiner bias is inherent in the study design because both examiner and patient were aware of the eye that was undergoing surgery. Other potential sources of bias in the measurement include improvement due to repeat testing and intersession variability. Nonetheless, the suggestion of improvement in treated eyes, taken with the absence of significant vision loss in treated eyes and lack of improvement in untreated control eyes, is a promising finding that merits further investigation.

Although the transplantation of sheets and suspensions of primary retinal pigment epithelium cells has been previously attempted,<sup>9-16</sup> such sources are extremely few and variable with respect to quality and expansion capacity.<sup>34</sup> Previous studies might have failed because in most cases the transplants were placed in the centre of large atrophic zones with presumably atrophic choriocapillaris, Bruch's membrane, and outer retinal (photoreceptor) anatomy. Unlike previous studies, our patients were transplanted in a transition zone that straddled atrophic central macular tissue and more

peripheral, fairly normal tissue. This was done with the hope that we could test an area of the diseased eye that more closely mimics compromised but not atrophic central visual tissue earlier in the course of disease. Studying long degenerated areas of central macular atrophy was unappealing because of the low likelihood of engraftment, survival, and biological activity of transplanted cells.

Unlike adult and fetal tissue, a central feature of hESC is that they have the capacity to proliferate indefinitely without undergoing senescence, providing an unlimited source of cells as starting material for directed differentiation. Cell lines can be tested to ensure that disease-associated genetic abnormalities are absent.<sup>17</sup> Another crucial advantage of using cells derived from hESC is that the stage of in-vitro differentiation can be controlled to maximise survival and functionality during and after transplantation.<sup>17</sup>

We have shown the medium-term to long-term safety, graft survival, and possible biological activity of pluripotent stem cell progeny in individuals with atrophic age-related macular degeneration and Stargardt's macular dystrophy. Our results suggest that hESC-derived cells could provide a potentially safe new source of cells for the treatment of a variety of unmet medical conditions caused by tissue loss or dysfunction. The goal should be to treat patients early in the disease, potentially increasing the likelihood of photoreceptor and central visual maintenance or rescue in amenable retinal disorders.

#### Contributors

RL and SDS wrote the manuscript and were involved in the study design, figures, and data gathering, analysis, and interpretation. BLL, CDR, DE, and PJR were involved in the patient surgery, editing, and data gathering, analysis, and interpretation. JLD, JM, J-PH, MS, NZG, and SDS were involved in the patient surgery. GH, JB, MV, and RG were involved in data gathering, analysis, and interpretation. DM and EA were involved in editing, figures, data analysis and interpretation. RMO was involved in the data gathering. LVDP was involved in writing, literature search, figures, and data analysis and interpretation. All authors have seen and approved the final version of the manuscript for publication.

#### Declaration of interests

SDS has received research support and consultancy fees from Alcon, Bausch and Lomb, Allergan, Genentech, Regeneron, and Avalanche. CDR has received research support from Mid Atlantic Retina. DE has received consultancy fees or honoraria from Alcon, Allergan, Arctic, Acucela, Alimera, Bausch and Lomb, Genentech, Regeneron, Ophthotech, Salutaris, Thrombogenics, Biogen, and ReNeuron. SDS, CDR, BLL, DE, and PJR received research support from Advanced Cell Technology for this study. RG, JB, DM, MV, EA, and RL are employees of Advanced Cell Technology, a biotechnology company in the specialty of stem cells and regenerative medicine. LVDP has received consultancy fees from Advanced Cell Technology.

#### Acknowledgments

Advanced Cell Technology funded the study. We thank Maureen McMahon and Jennifer Grossman for patient evaluation and follow-up; Donald Kohn, Aisha Khan, Omayma Hanif, and Darlene Miller for good manufacturing practice therapeutic material preparation; Tong Li, Deborah Peak, and Judson Ratliff for their help in preparation and technical transfer of the retinal pigment epithelium cells; and Robert Almanzor, Jennifer Verriotto, Cristy Lage-Rodriguez, Nina Zelcer, and Logan Hitchcock for clinical coordination and data monitoring.



## References

- 1 Evans MJ, Kaufman MH. Establishment in culture of pluripotential cells from mouse embryos. *Nature* 1981; **292**: 154–56.
- 2 Lanza R, Gearhart J, Hogan B, et al, eds. *Essentials of stem cell biology*, 2nd edn. San Diego: Academic Press/Elsevier, 2009.
- 3 Kaplan HJ, Tezel TH, Berger AS, Del Priore LV. Retinal transplantation. In: Streilein JW, ed. *Immune response and the eye*. Chem Immunol. Basel: Karger, 1999: 207–19.
- 4 Lund RD, Wang S, Klimanskaya I, et al. Human embryonic stem cell-derived cells rescue visual function in dystrophic rats. *Cloning Stem Cells* 2006; **8**: 189–99.
- 5 Lu B, Malcuit C, Wang S, et al. Long-term safety and function of RPE from human embryonic stem cells in preclinical models of macular degeneration. *Stem Cells* 2009; **21**: 2125–35.
- 6 Sparrow JR, Hicks D, Hamel CP. The retinal pigment epithelium in health and disease. *Curr Mol Med* 2010; **10**: 802–23.
- 7 Strauss O. The retinal pigment epithelium in visual function. *Physiol Rev* 2005; **85**: 845–81.
- 8 Pan CK, Heilwell G, Lanza R, Schwartz SD. Embryonic stem cells as a treatment for macular degeneration. *Expert Opin Biol Ther* 2013; **13**: 1125–33.
- 9 Binder S, Krebs I, Hilgers RD, et al. Outcome of transplantation of autologous retinal pigment epithelium in age-related macular degeneration: a prospective trial. *Invest Ophthalmol Vis Sci* 2004; **45**: 4151–60.
- 10 Alverve PV, Berglin L, Gouras P, Sheng Y. Transplantation of fetal retinal pigment epithelium in age-related macular degeneration with subfoveal neovascularization. *Graefes Arch Clin Exp Ophthalmol* 1994; **232**: 707–16.
- 11 Binder S, Stolba U, Krebs I, et al. Transplantation of autologous retinal pigment epithelium in eyes with foveal neovascularization resulting from age-related macular degeneration: a pilot study. *Am J Ophthalmol* 2002; **133**: 215–25.
- 12 MacLaren RE, Bird AC, Sathia PJ, Aylward GW. Long-term results of submacular surgery combined with macular translocation of the retinal pigment epithelium in neovascular age-related macular degeneration. *Ophthalmology* 2005; **112**: 2081–87.
- 13 Lappas A, Weinberger AW, Foerster AM, Kube T, Rezaei KA, Kirchhof B. Iris pigment epithelial cell translocation in exudative age-related macular degeneration. A pilot study in patients. *Graefes Arch Clin Exp Ophthalmol* 2000; **238**: 631–41.
- 14 Aisenbrey S, Lafaut BA, Szurman P, et al. Iris pigment epithelial translocation in the treatment of exudative macular degeneration: a 3-year follow-up. *Arch Ophthalmol* 2006; **124**: 183–88.
- 15 Thumann G, Aisenbrey S, Schraermeyer U, et al. Transplantation of autologous iris pigment epithelium after removal of choroidal neovascular membranes. *Arch Ophthalmol* 2000; **118**: 1350–55.
- 16 Berger AS, Tezel TH, Del Priore LV, Kaplan HJ. Photoreceptor transplantation in retinitis pigmentosa: short-term follow-up. *Ophthalmology* 2003; **110**: 383–91.
- 17 Schwartz SD, Hubschman J-P, Heilwell G, et al. Embryonic stem cell trials for macular degeneration: a preliminary report. *Lancet* 2012; **379**: 713–20.
- 18 Mangione CM, Berry SH, Spritzer K. Identifying the content area for the 51-item National Eye Institute Visual Function Questionnaire: results from focus groups with visually impaired persons. *Arch Ophthalmol* 1998; **116**: 227–33.
- 19 Mangione CM, Lee PP, Guitierrez PR, et al; National Eye Institute Visual Function Questionnaire Field Test Investigators. Development of the 25-item National Eye Institute Visual Function Questionnaire. *Arch Ophthalmol* 2001; **119**: 1050–58.
- 20 Thomson JA, Itskovitz-Eldor J, Shapiro SS, et al. Embryonic stem cell lines derived from human blastocysts. *Science* 1998; **282**: 1145–47.
- 21 Klimanskaya I, Chung Y, Becker S, Lu SJ, Lanza R. Human embryonic stem cell lines derived from single blastomeres. *Nature* 2006; **444**: 481–85.
- 22 Hentze H, Soong PL, Wang ST, Phillips BW, Putti TC, Dunn NR. Teratoma formation by human embryonic stem cells: evaluation of essential parameters for future safety studies. *Stem Cell Res* 2009; **2**: 198–210.
- 23 Chakravarthy U, Evans J, Rosenfeld PJ. Clinical review: age related macular degeneration. *BMJ* 2010; **340**: c981.
- 24 Bull ND, Martin KR. Concise review: toward stem cell-based therapies for retinal neurodegenerative diseases. *Stem Cells* 2011; **29**: 1150–75.
- 25 Stein JD, Zacks DN, Grossman D, et al. Trends in rates of adverse events after pars plana vitrectomy among medicare beneficiaries. *Arch Ophthalmol* 2009; **127**: 1656–63.
- 26 Maguire JI. Postoperative endophthalmitis: optimal management and the role and timing of vitrectomy surgery. *Eye (Lond)* 2008; **22**: 1290–300.
- 27 Del Priore LV. Effect of sham surgery on retinal function after subretinal transplantation of the artificial silicone retina. *Arch Ophthalmol* 2005; **123**: 1156.
- 28 Grisanti S, Szurman P, Jordan J, Kociok N, Bartz-Schmidt KU, Heimann K. Xenotransplantation of retinal pigment epithelial cells into RCS rats. *Jpn J Ophthalmol* 2002; **46**: 36–44.
- 29 Maguire AM, Simonelli F, Pierce EA, et al. Safety and efficacy of gene transfer for Leber's congenital amaurosis. *N Engl J Med* 2008; **358**: 2240–48.
- 30 Finger RP, Fleckenstein M, Holz FG, Scholl HP. Quality of life in age-related macular degeneration: a review of available vision-specific psychometric tools. *Qual Life Res* 2008; **17**: 559–74.
- 31 Lindblad AS, Clemons TE. Responsiveness of the National Eye Institute Visual Function Questionnaire to progression to advanced age-related macular degeneration, vision loss, and lens opacity: AREDS report no 14. *Arch Ophthalmol* 2005; **123**: 1207–14.
- 32 Mahmoud TH, McCuen BW 2nd, Hao Y, et al. Lensectomy and vitrectomy decrease the rate of photoreceptor loss in rhodopsin P347L transgenic pigs. *Graefes Arch Clin Exp Ophthalmol* 2003; **241**: 298–308.
- 33 Silverman MS, Hughes SE. Photoreceptor rescue in the RCS rat without pigment epithelium transplantation. *Curr Eye Res* 1990; **9**: 183–91.
- 34 Tezel TH, Del Priore LV. Serum-free media for culturing and serially-passaging of adult human retinal pigment epithelium. *Exp Eye Res* 1998; **66**: 807–15.